

# P401 Electrochemotherapy: experience from an International Network for Sharing Practice on Electrochemotherapy center located in Mirano (Venice)

Barbara Silvestri<sup>1</sup>, Silvia Carpenè<sup>2</sup>, Martina Bertinazzi<sup>2</sup>, Roberto Spinato<sup>3</sup>, Corrado Da Lio<sup>3</sup>, Francesca de Terlizzi<sup>4</sup>, Valbona Lico<sup>5</sup>, Mario Biral<sup>5</sup>, Fjorenta Sulo<sup>5</sup>, Giuseppe Azzarello<sup>1</sup>

<sup>1</sup> and <sup>3</sup>, Oncology and Haematology Unit, Azienda Unità Sanitaria Locale Socio Sanitaria (AULSS) 3 Serenissima - Ospedale di Mirano, Venice, Italy. Email: [barbara.silvestri@aulss3.veneto.it](mailto:barbara.silvestri@aulss3.veneto.it)

<sup>2</sup> Otolaryngology Unit, Azienda Unità Sanitaria Locale Socio Sanitaria (AULSS) 3 Serenissima - Ospedale di Mirano, Venice, Italy

<sup>3</sup> Otolaryngology Unit, Azienda Unità Sanitaria Locale Socio Sanitaria (AULSS) 3 Serenissima - Ospedale di Mestre, Venice, Italy

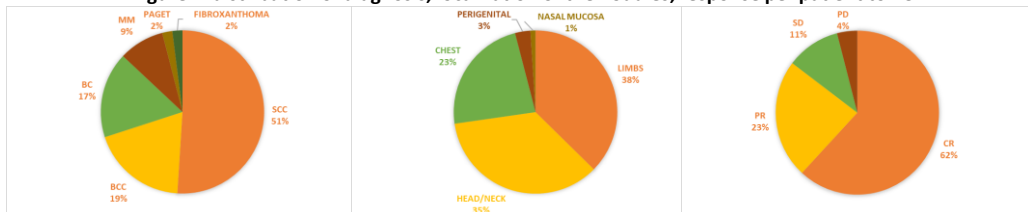
<sup>4</sup> IGEA Biophysics Lab. Carpi, Modena, Italy

<sup>5</sup> Surgery Unit, Azienda Unità Sanitaria Locale Socio Sanitaria (AULSS) 3 Serenissima - Ospedale di Mirano, Venice, Italy

Our equipe has performed a great deal of experience on elderly patients treated with Electrochemotherapy (ECT), that has been accumulated in the last 6 years of activity (2018-2023). Forty-seven patients have been analyzed, with a mean age of 84±13 years.

Several pathologies were treated with ECT: 24 Squamous Cell Carcinoma (51%), 9 Basal Cell Carcinoma (19%), 8 Breast Cancer (17%), 4 Melanoma (9%), 1 extra-mammalian Paget disease (2%) and 1 Fibroxanthoma (2%). Seventy-four nodules have been treated: limbs (37%), head/neck (35%), chest (23%), perigenital region (3%), nasal mucosa (1%). All patients underwent ECT with systemic Bleomycin injection, 40 under local anesthesia with deep sedation and 7 under general anesthesia.

**Figure 1. distribution of diagnosis, localization of the nodules, response per patient to ECT**




The collaboration with Otolaryngology and Surgery units has allowed us to accumulate significant experience also in the treatment of mucosal lesions of the head/neck region as well as of the perigenital one.

In fact, Mucosal Melanoma (MM) is a rare but aggressive disease. Surgery with free margins, when feasible, is the treatment of choice. In the last three decades, electrochemotherapy (ECT) has emerged as a local ablative procedure, performed with the Cliniporator (IGEA S.p.a.), for cutaneous and mucosal tumours of different histology.

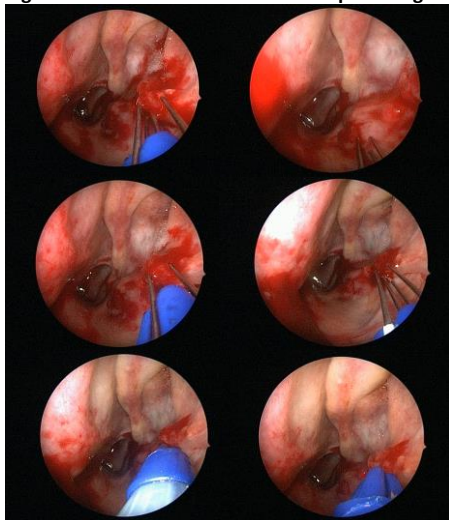
Recently, a new endoscopic electrode has been developed by IGEA S.p.a., the "Stinger" electrode, with the aim of treating lesions in the larynx/pharynx, as well as in the rectum and vulvar region.

In the INSPECT registry a project on mucosal lesions of the head/neck, treated with ECT, is collecting more than 70 patients.



**Figure 2. The «Stinger» electrode.**

**Figure 3. ECT treatment with endoscopic «Stinger» electrode.**



Our center was one of the first using the new endoscopic electrode ("Stinger") on an 88 years-old man affected by Sino-Nasal-Mucosal-Melanoma (cT4aN0M0) Stage-IV, of the nasal fossa, strength of the experience on elderly patients in ORL setting. He presented with a bleeding lesion in the left nasal cavity partial occupation of the oropharynx, such as to completely prevent breathing from the nasal cavities and make feeding extremely difficult. After the procedure, he had been free from symptoms for five months, with a good quality of life. Local recurrence was controlled with a new local debulking and ECT procedure on margins. Seventeen months after diagnosis, the patient is mild symptomatic for sinonasal disease and this result goes beyond the expectations of a systemic therapy, not possible in an elderly person.

We have also used the «stinger» electrode on a MM of the rectum with preliminary good results.

In our experience, ECT can be used in very elderly patients for symptom and local control of disease, with a good tolerance and good results in terms of quality-of-life parameters. Furthermore, the new endoscopic "Stinger" electrode proved to be efficient in the treatment of mucosal melanoma or other mucosal heteroplasia.